



PATIENT

Maeby Marshall

SPECIES

Canine

BREED

Border Collie Mix

SEX

Female Spayed

AGE

13 years

WEIGHT

45lbs

INTERPRETED BY

Maggie Machen
Lamy, DVM
DACVIM (Cardiology)

IMAGING PERFORMED BY

Pamela Harrigan,
RDCS

HOSPITAL NAME

Parkway Veterinary
Hospital

REFERRING VET

Dr. Diese

INVOICE

26901

DATE

10/14/22

PRESENTING CLINICAL SIGNS

History: Presented for annual exam. New grade II-III/VI systolic murmurs. Pulses s/s. Lyme + (historical). Moderate- significant dental disease. Maeby is doing well at home. Current medications: NOVOX (Carprofen) 100mg caplets 1/2 BID.

ECHOCARDIOGRAM FINDINGS

2D, m-mode, color flow and Doppler imaging is available.

Left ventricle: The LV diameter is normal with adequate myocardial function. LV wall thicknesses are normal.

Left atrium: The left atrium is minimally dilated.

Mitral valve: The mitral valve is mildly thickened with minimal prolapse into the left atrial lumen. Mild to moderate eccentric mitral regurgitation with a normal velocity.

Aortic valve/aorta: The aortic valve is normal in morphology and mobility. Normal aortic outflow velocity; laminar flow. No aortic insufficiency.

Right ventricle: Normal right ventricular diameter and morphology indicating no overt evidence of pulmonary arterial hypertension.

Right atrium: Normal RA dimension.

Tricuspid valve: The tricuspid valve appears normal with mild tricuspid regurgitation; normal velocity.

Pulmonic valve/pulmonary artery: The pulmonic valve is normal in morphology and mobility. No pulmonic insufficiency. Normal RVOT velocity; laminar flow.

Pericardium/other: No pericardial or pleural effusion noted. No obvious cardiac masses.

Heart rhythm: ECG reveals a sinus rhythm with an average HR of 120bpm. Sinus pauses and a single VPC identified.

2-Dimensional Measurements

Ao diam (cm)	2.3
LA diam (cm)	2.9
LA:Ao (Swe)	1.3
IVS thickness (cm)	1.0
LVID diastole (cm)	4.1
PW thickness (cm)	1.0
LVID systole (cm)	2.2
FS (%)	46

Doppler Measurements

PV Vmax (m/s)	0.7
AoV Vmax (m/s)	1.2
MR Vmax (m/s)	5.8
TR Vmax (m/s)	2.7
TR PG (mmHg)	29

INTERPRETATION OF THE FINDINGS

The cause of the murmur is chronic degenerative valve disease causing mild to moderate mitral and mild tricuspid regurgitation. Lack of significant left atrial enlargement indicates the current risk for complication is low. No concurrent issues such as systolic dysfunction or pulmonary hypertension are noted in this study. The ECG does show a single VPC and sinus pauses, and an extended tracing may be warranted.

Assessment of progression in the future will help predict long term prognosis, which is highly variable at this stage (B1).



PATIENT

Maeby Marshall

SPECIES

Canine

BREED

Border Collie Mix

SEX

Female Spayed

AGE

13 years

WEIGHT

45lbs

INTERPRETED BY

Maggie Machen
 Lamy, DVM
 DACVIM (Cardiology)

IMAGING PERFORMED BY

Pamela Harrigan,
 RDCS

HOSPITAL NAME

Parkway Veterinary
 Hospital

REFERRING VET

Dr. Diese

INVOICE

26901

DATE

10/14/22

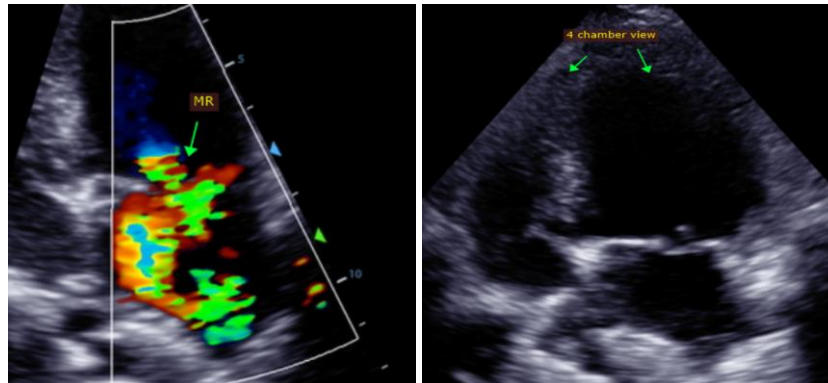
RECOMMENDATIONS

- In a dog without significant left atrial enlargement, no cardiac medications are clearly indicated.
- Consider an extended ECG recording.
- Omega fatty acid supplementation and mild salt restriction may be of some long-term benefit.
- Anesthetic risk is considered mild if needed. Cardiac protective drug choices (opioid/benzodiazepine premedication, propofol or alfaxalone induction, isoflurane gas) are recommended. Pre-oxygenate for 5-10 minutes prior to induction. Monitor for arrhythmias, hypotension, and hypoxia both intra and post-operatively and intervene as necessary. Mild IV fluid restriction is recommended to avoid fluid overload. Avoid heart rate stimulating drugs such as atropine unless clinically indicated.
- Monitor for development of a cough, labored breathing, exercise intolerance or collapse episodes.

PLAN

- Recommend conservative monitoring with a recheck echocardiogram in 6 months, sooner if any development of clinical signs.

IMAGES



The information and recommendations provided are based on the images presented by the referring veterinarian. No evaluation can be communicated regarding pathology that was not visible in the image/video clips provided.

Thank you for this referral. This report was generated using transcription software, and minor dictation errors may be present. If the clinical or image interpretation does not parallel your findings or if I can be of any further assistance, please contact me.

Maggie Machen Lamy, DVM
 Diplomat of the American College of Veterinary Internal Medicine (Cardiology)
 info@sonopath.com